

## An in vitro comparative evaluation of a hand file and three rotary NiTi instruments for removing gutta percha during root canal re-treatment

\*Yadav P, \*\*Bharath MJ, \*\*Sahadev CK, \*\*Kumar P, \*\*\*Rao Y

\* Department of Conservative Dentistry and Endodontics, Maulana Azad Institute of Dental Sciences, New Delhi, India; \*\* Department of Conservative Dentistry and Endodontics, Sri Hasanamba Dental College and Hospital, Vidyanagar, Hassan, Karnataka, India;\*\*\*Department of Prosthodontics, Maharana Pratap College of Dentistry and Research Centre

\* Correspondence: Yadav P

E mail : dr\_pankaj\_111@yahoo.co.in

### Abstract

**Objective:** To evaluate the efficacy of NiTi mechanical rotary instrumentation and Hedstrom file for gutta percha removal using clearing technique

**Method:** Forty extracted human single rooted premolar, each with a single canal were selected. The samples were decoronated to leave 17 mm root and instrumented with K-files upto MAF 30 using step back technique. Samples were obturated using cold lateral condensation of gutta-percha and AH Plus sealer. The teeth were then randomly divided into four groups of 10 specimens each. After 2 weeks all the canals were then retreated by either ProTaper re-treatment files, M-two re-treatment files, R-Endo re-treatment files or Hedstrom files. The amount of remaining filling materials after re-treatment procedures was assessed by stereomicroscope. Also time required for reaching original working length and for removal of obturating material (in min) was measured. Statistical analysis was accomplished using one way Kruskal-Wallis ANOVA and Mann-Whitney U test

**Result:** M-two re-treatment files showed least amount of gutta percha/sealer followed by ProTaper re-treatment files, R-Endo re-treatment files and Hedstrom files.

**Conclusion:** Under the experimental conditions, significant difference was observed between ProTaper re-treatment files & Hedstrom files and Mtwo re-treatment files & Hedstrom files for gutta percha/sealer removal. Complete removal of materials did not occur with any of the instrument systems investigated.

**Key words:** Clearing technique, re-treatment, rotary instruments

### Introduction

Successful endodontic treatment requires thorough debridement of infected or necrotic pulp tissue and microorganisms and to completely seal canal space<sup>(1)</sup>. Root canal failure can be treated with conventional re-treatment, periradicular surgery or extraction. Most preferred treatment for failed endodontic cases is nonsurgical re-treatment<sup>(2)</sup>. Re-treatment of previously filled canals requires gutta-percha and sealer removal from canal walls and anatomical ramifications. Greatest difficulty faced by endodontists during re-treatment is complete removal of old filling material<sup>(3)</sup>.

Gutta-percha removal can be done using stainless steel hand files<sup>(4,5)</sup>, nickel-titanium (NiTi) rotary instruments<sup>6-9</sup>, engine-driven rotary files, heat-bearing instruments<sup>(10-12)</sup>, ultrasonic instruments<sup>(13-15)</sup> and lasers<sup>(16)</sup>.

With evolution in endodontics, development of new rotary instruments appears to be an excellent auxiliary resource for mechanical preparation of root canals in re-treatment procedures<sup>(17)</sup>. Use of solvent and usage of rotary instruments in re-treatment process has advantages concerning clinical time reduction<sup>(18,19)</sup>. Amongst instruments used for re-treatment, nickel-titanium rotary instruments have been found to be practical, effective and may decrease operator fatigue<sup>(20,21)</sup>. Three new nickel-

titanium (NiTi) systems have recently been designed especially for gutta percha removal. They are ProTaper Universal re-treatment files (Dentsply-Maillefer, Ballaigues, Switzerland), M-two re-treatment rotary files (Sweden & Martina, Padova, Italy) and R-Endo (Micro-Mega, Besancon, France) re-treatment files.

ProTaper re-treatment files have a convex triangular cross section that reduces area of contact between instrument and dentin walls<sup>(22)</sup>. These files soften the gutta-percha by rotation and cut it. The active tip of the D1 file facilitates the penetration of the subsequent files (D2 and D3). The nonactive tips of D2 and D3 reduce the incidence of ledging, perforation and stripping during the removal of filling materials<sup>(17)</sup>.

M-two Re-treatment system has active tips for all re-treatment instruments (M-two R25/.05 and M-two R15/.05) for efficient removal of root canal filling. M-two re-treatment files have a cutting tip so the instrument progresses easily in the obturation material without pressure<sup>(3)</sup>. All the files are used to full working length. M two Re-treatment instruments are used without downward pressure. These files gradually remove the root canal filling with circumferential filing movements<sup>(23)</sup>.

All R-Endo re-treatment files have a cutting tip, triangular cross section with three equally spaced cutting edges and no radial land<sup>(22)</sup>. This instrument system has sufficient

rigidity to remove material from the root canal, but with adequate flexibility so as not to create aberrations in the canal<sup>(24)</sup>.

Efficacy of a re-treatment procedure is assessed by cleanliness of root canal walls<sup>(25)</sup>. Remaining filling debris has been assessed by conventional radiography, splitting teeth longitudinally or making teeth transparent. Amongst them, clearing technique appears to be cost-effective and sensitive to identify small areas of residual gutta percha or sealer<sup>(26)</sup>.

The aim of the present study was to compare the time taken and cleanliness of root canal walls achieved after gutta percha removal with ProTaper Universal re-treatment files, M-two re-treatment files, R-Endo re-treatment files and Hedstrom files using stereomicroscope.

### Materials and method

Forty extracted straight, single rooted mandibular premolars with closed apices were selected. The teeth were verified radiographically as having patent canals of curvature 10° (Sneider 1971), absence of fillings, internal resorption and localized/diffused calcification.

Access preparation was done on each tooth and a size 10 K file was placed in canal until it was visible at apical foramen and working length was determined by subtracting 1 mm from this measurement. Samples were decoronated to leave 17 mm root and root canal was prepared using K files with step back technique. Instrumentation was standardized with a size 30 K file reaching full working length, a size 55 file 5 mm coronally and final coronal flaring with Gates Glidden 2 and 3. When instrumentation of root canal was completed, 17% EDTA was applied for 3 min and canals were again irrigated with 2 ml of 2.5% NaOCl followed by final rinse with 5 ml saline.

Thereafter, root canals were obturated by lateral condensation technique, with gutta percha cones and AH Plus sealer. Mesiodistal radiographs were taken to assess quality and apical extent of root canal fillings. Coronal access was sealed with a temporary filling material (Cavit G; 3M Espe, Seefeld, Germany). Specimens were stored in an incubator at 37 degree centigrade in 100% humidity for 2 weeks.

The temporary filling material was removed with a size 4 round bur (Mani Dia Bur) and 5 mm of filling material was removed from cervical part of all samples using Gates Glidden bur sizes 2 and 3 at 5000 r.p.m. Then a drop of xylene solvent was introduced into each canal and left to act for 2 min. During re-treatment canals were constantly irrigated with 2 ml of 2.5% NaOCl. All the rotary instruments were used at a constant speed of 300 r.p.m. and torque recommended by the manufacturers. Rotary instrumentation of re-treatment files was performed using a 16:1 reduction gear hand-piece with an electric motor (X-Smart; Dentsply Maillefer). Each instrument was used for a maximum of five canals.

All the 3 ProTaper Universal System re-treatment files (Group I) were used in crown down technique using a brushing action with lateral pressing movements. D1 ProTaper file was in cervical third and D2 ProTaper file was used in the coronal two thirds of the root canal. D3 ProTaper file was used with light apical pressure until working length was reached and no further filling material could be removed.

M-two Re-treatment file (Group II) re-treatment was

initiated by placing tip of the R2 size 25 .05 taper re-treatment instrument on gutta percha. The canals were instrumented to working length using M-two R2 file with circumferential filing and a lateral pressing movement.

R-Endo re-treatment instruments (Group III) (Re, R1, R2 and R3) were used to remove gutta-percha and its sealer in brushing circumferential movement. Size 25, 0.08 taper R1 NiTi rotary file was used to penetrate from coronal third to beginning of middle third through repeated apically directed pushing actions. Size 25, 0.06 taper R2 NiTi rotary file was used from middle third to beginning of apical third. Finally, R3 was used upto working length.

The canals were re-instrumented in a crown-down technique with H-type file (Group IV) ISO sizes 45, 40, 35, 30 and 25 in a circumferential quarter turn push-pull filing motion to remove gutta percha and sealer from canal until working length was reached with a size 25 H-type file. Hedstrom file group served as the control group. Re-treatment was considered complete when no filling material was observed on instrument and the canal walls were smooth and free of visible debris. Time needed for the procedure was measured with a stopwatch.

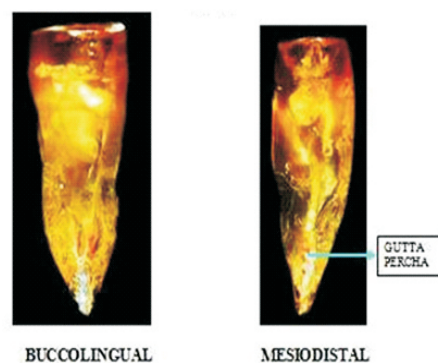
Then teeth were rendered transparent according to technique described by Robertson et al<sup>(27)</sup> (1980). Specimens were photographed using a stereomicroscope with digital camera at 6.5X magnification. For all specimens following data was recorded:

(i) Canal wall cleanliness: The Gutta Percha/sealer (**Figure 1**) remnants on canal walls were imaged on a black background in buccolingual and mesiodistal directions using a stereomicroscope (**Figure 2**) at 6.5X magnification via a CCD-sensor (SZX7 Olympus America Inc.). Amount of gutta percha/sealer on canal wall was measured in mm<sup>2</sup> using image analysis software (Image Tool 3.00 UTHSC San Antonio) connected to stereomicroscope

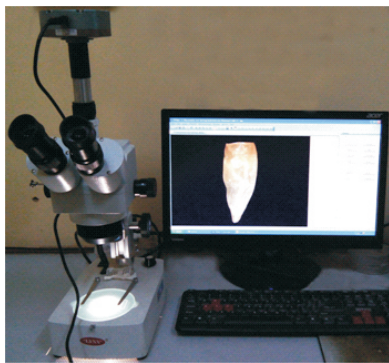(ii) Time required for reaching original working length: Time elapsed from entering canal with Gates Glidden drill until reaching the original working length was measured (in min) with a stopwatch.

(iii) Total time for removing filling material: Time required for reaching the original working length and for removal of obturating material (in min) from starting first Gates Glidden drill until completion of re-instrumentation was measured.

Data were statistically analyzed using one way Kruskal-Wallis ANOVA and Mann-Whitney U test.



**Figure 1. Images of gutta-percha and sealer remaining on the root canal walls**



**Figure 2. Stereomicroscope in use**

**Result**

Complete removal of obturating material didn't occur with any of the systems used. Time required to reach working length was least with M-two re-treatment files, followed by ProTaper re-treatment files, R-Endo re-treatment files and Hedstrom files (**Table 1**). There was no statistically significant difference between files with respect to time required for reaching original working length ( $p > 0.05$ ) and total time required for re-treatment ( $p > 0.05$ ). Total time taken for re-treatment was least with R-Endo re-treatment files followed by M-two re-treatment files, Protaper re-treatment files and Hedstrom files (**Table 1**).

When viewed in mesiodistal and buccolingual direction M-two re-treatment files effectively removed gutta percha from root canals (**Table 2**). There was a significant difference between 4 files with respect to remaining obturation material in buccolingual direction ( $p < 0.05$ ). Significant difference was observed between ProTaper re-treatment files & Hedstrom files and M-two re-treatment files & Hedstrom files ( $p < 0.05$ ). When viewed in mesiodistal direction significant difference was observed between ProTaper re-treatment files & Hedstrom files, M-two re-treatment files & Hedstrom files even in R-Endo re-treatment files & Hedstrom files ( $p < 0.05$ ).

**Table 1. Time taken to reach working length (T1) and to remove the filling material (T2) with each technique**

Method	N	Time (min) T1	Time (min) T2
Group I	10	3.81 ± 1.87	7.41 ± 2.83
Group II	10	3.28 ± 2.29	6.54 ± 3.3
Group III	10	4.21 ± 1.7	6.47 ± 2.24
Group IV	10	5.65 ± 3.26	10.29 ± 5.48

Values are expressed as mean ± SD.

**Table 2. The amount of remaining filling material**

Method	Mesiodistal M-D (mm <sup>2</sup> )	Buccolingual B-L (mm <sup>2</sup> )
Group I	0.67 ± 0.79	0.41 ± 0.47
Group II	0.43 ± 0.47	0.32 ± 0.38
Group III	0.89 ± 0.83	0.52 ± 0.58
Group IV	2.16 ± 1.27	1.23 ± 1.09

Values are expressed as mean ± SD.

The following are the values for the canal wall cleanliness that was done using a stereomicroscope

**1) ProTaper retreatment file**

Buccolingual Gp remaining (10 <sup>-6</sup> mm <sup>2</sup> )	MD Gp remaining (10 <sup>-6</sup> mm <sup>2</sup> )
1595826	2536151
52773.34	47554
452066.3	970288
159498.4	89554
611564.7	1022810
124652.8	108829
208905	1085178
48228.26	173722
257133.26	669135
638919.32	36276

**2) M-two re-treatment file**

Buccolingual Gp remaining (10 <sup>-6</sup> mm <sup>2</sup> )	MD Gp remaining (10 <sup>-6</sup> mm <sup>2</sup> )
292483.8	145526
809191.1	635552
34508.88	65735
843699.98	1247454
21715.34	38296
899924.2	828970
54625.03	74236
11026.01	16581
87282.22	205874
102516.6	1051679

**3) Rendo re-treatment file**

Buccolingual Gp remaining (10 <sup>-6</sup> mm <sup>2</sup> )	MD Gp remaining (10 <sup>-6</sup> mm <sup>2</sup> )
67502.74	767528
170019	2818449
47386.58	304267
217405.58	867687
1327329	1841343
1544734.58	533456
167494.3	101590
66576.89	287686
490867.8	769211
1124737	655332

**4) Hedstrom re-treatment file**

Buccolingual Gp remaining (10 <sup>-6</sup> mm <sup>2</sup> )	MD Gp remaining (10 <sup>-6</sup> mm <sup>2</sup> )
156047	570069
1317398	3671576
4219426	4859187
560138	373032
943439	1951014
157478	206464
1235923	1668210
443312	82603484
706422	2569565
831074	103358

## Discussion

In present study for the evaluation of canal wall cleanliness tooth clearing technique was used. Clearing technique is simple, but there are some potential problems such as determination of end point of decalcification. Although there are tests to determine end point of decalcification, we followed an empirical method of decalcifying teeth 24 hours after the enamel appeared to have dissolved<sup>(28)</sup>. Canal wall cleanliness was evaluated after clearing the samples and observing under stereomicroscope.

No rotary instrument separated during re-treatment procedure. As each set of instrument was used to prepare two root canals only and use of xylene as a solvent, might be a reason for lack of instrument fracture. However, two Hedstrom files (ISO 20 and 15) separated during re-treatment procedure. No perforations, blockages or ledging were observed. Our results showed that use of NiTi rotary re-treatment files appeared to be safe during the re-treatment procedure.

R-Endo re-treatment files and M-two re-treatment files required less time to remove root filling material than using manual technique. Active tip and cutting blades of R-Endo re-treatment files and M-two re-treatment files positively influenced time required for re-treatment. ProTaper Universal re-treatment files were time consuming as the tip size of D3 is size 20 which was the last file used during re-treatment.

In this study, all rotary NiTi instruments were significantly faster than hand files in removing gutta-percha. This was due to movements of rotary driven files which produce a degree of frictional heat sufficient to plasticize gutta percha. The plasticized gutta percha presents less resistance and is easier to remove. As per results, it was impossible to completely remove all traces of gutta percha/sealer from root canals with any of re-treatment files as revealed under stereomicroscopic examination. The majority of remaining filling material on canal walls appeared to be sealer as it adheres well to canal wall particularly when solvents are used.

Saad et al evaluated efficacy of Protaper and K3 rotary in the removal of gutta percha during root canal re-treatment in comparison with Hedstrom files. It was concluded that Protaper and K3 were effective and faster in removing gutta percha<sup>(2)</sup>; concurs with our study. This was due to design of Protaper and K3.

Tasdemir et al evaluated efficacy of ProTaper, M-two, R-Endo rotary NiTi instruments & H files to remove Gutta percha & sealer in re-treatment of root canals. The results showed that ProTaper left significantly less gutta percha & sealer than M-two instruments. Complete removal didn't occur with any of the instrument systems<sup>(23)</sup>; does not agree with our study.

Somma et al compared the efficacy of two new engine driven NiTi rotary systems: the M-two R and the ProTaper re-treatment files with a manual technique in the removal of 3 root filling materials (gutta-percha, Resilon and EndoRez). The results indicated that all instruments left remnants of filling material and debris on the root canal walls. Both the engine-driven NiTi rotary systems proved to be safe and fast devices for the removal of endodontic filling material<sup>(29)</sup>; confirmed by our study.

Cleaning ability of Ni-Ti rotary files depend on the characteristics of cross-sectional design of the instruments<sup>(17)</sup>. Among all systems, better performance of

M-two re-treatment files in our study is due to the design of the instrument. M-two re-treatment files have an S shaped cross-section, an increasing pitch length in apicalcoronal direction and a cutting tip. Therefore, these instruments are characterized by a positive rake angle with two cutting edges. Cutting blades form long, vertical spirals ensuring better control of instrument progression. As they have sharp blades, it is possible to cut through canal and reach apical end-point whilst by passing obturation material. Also, unlike other NiTi instruments, M-two rotary instruments do not require a crown-down instrumentation sequence.

## Conclusion

1. All systems left gutta percha/sealer remnants on root canal walls.
2. All three rotary NiTi systems proved helpful and safe devices for gutta-percha removal.
3. Time required to reach working length was least with M-two re-treatment files, followed by ProTaper re-treatment files, R-Endo re-treatment files and Hedstrom files.
4. Total time taken for removal of filling material was least with R-Endo re-treatment files followed by M-two re-treatment files, ProTaper re-treatment files and Hedstrom files.
5. M-two re-treatment files left less gutta percha on canal walls followed by ProTaper Re-treatment files, R-Endo re-treatment files and Hedstrom files.

## References

1. Lin LM, Skribner JE, Gaengler P. Factors associated with endodontic treatment failures. *J Endod* 1992; 18:625-627.
2. Saad AY, Al-Hadlaq SM, Al-Katheeri NH. Efficacy of two rotary NiTi instruments in the removal of gutta-percha during root canal re-treatment. *J Endod* 2007; 33:38-41.
3. Barletta FB, Rahde Nde M, Limongi O, Moura AA, Zanesco C, Mazocatto G. In vitro comparative analysis of 2 mechanical techniques for removing gutta-percha during re-treatment. *J Can Dent Assoc* 2007; 73:65 (65a.65e).
4. Imura N, Kato AS, Hata GI, Uemura M, Toda T, Weine F (2000) A comparison of the relative efficacies of four hand and rotary instrumentation techniques during endodontic re-treatment. *Int Endod J* 33, 361-366.
5. Schirrmester JF, Hermanns P, Meyer KM, Goetz F, Hellwig E. Detectability of residual Epiphany and gutta-percha after root canal re-treatment using a dental operating microscope and radiographsan ex vivo study. *Int Endod J* 2006; 39:558-565.
6. Hulsmann M, Bluhm V. Efficacy, cleaning ability and safety of different rotary NiTi instruments in root canal re-treatment. *Int Endod J* 2004; 37:468-476.
7. Schirrmester JF, Wrbas KT, Meyer KM, Altenburger MJ, Hellwig E. Efficacy of different rotary instruments For gutta-percha removal in root canal retreatment. *J Endod* 2006; 32:469-472.

8. Hulsmann M, Stotz S. Efficacy, cleaning ability and safety of different devices for gutta-percha removal in root canal re-treatment. *Int Endod J* 1997; 30:227-233.
9. Tasdemir T, Yildirim T, Celik D. Comparative study of removal of current endodontic fillings. *J Endod* 2008; 34:326-329.
10. Friedman S, Stabholz A, Tamse A. Endodontic re-treatment: case selection and technique part 3: re-treatment techniques. *J Endod* 1990; 16:543-549.
11. Ring J, Murray PE, Namerow JN, Moldauer BI and Garcia-Godoy F. Removing root canal obturation materials: A comparison of rotary file systems and Re-treatment agents. *J Am Dent Assoc* 2009; 140:680-688.
12. Friedman S, Mor C. The success of endodontic therapy: healing and functionally. *J Calif Dent Assoc* 2004; 32:267-274.
13. Krell KV, Neo J. The use of ultrasonic endodontic instrumentation in the re-treatment of a paste-filled endodontic tooth. *Oral Surg Oral Med Oral Pathol* 1985; 60:100-102.
14. Jeng HW, ElDeed ME. Removal of hard paste fillings from the root canal by ultrasonic instrumentation. *J Endod* 1987; 13:295-298.
15. Wilcox LR. Endodontic re-treatment: ultrasonic and chloroform as a final step in re-instrumentation. *J Endod* 1989; 15:125-128.
16. Takahashi CM, Cunha RS, DeMartin AS, Fontana CE, Silveira CFM and Bueno CE. In vitro evaluation of the effectiveness of ProTaper Universal rotary re-treatment system for gutta-percha removal with or without a solvent. *J Endod* 2009; 35:1580-1583.
17. Zanettini PR, Barletta FB and Rahde NM. In vitro comparison of different reciprocating systems used during endodontic re-treatment. *Aust Endod J* 2008; 34:80-85.
18. Giuliani V, Cocchetti R and Pagavino G. Efficacy of ProTaper Universal re-treatment files in removing filling materials during root canal re-treatment. *J Endod* 2008; 34:1381-1384.
19. Schirrmeister JF, Wrbas KT, Schneider FH, Altenburger MJ and Hellwig E. Effectiveness of a hand file and three nickel-titanium rotary instruments for removing gutta-percha in curved root canals during re-treatment. *Oral Surg Oral Med Oral Pathol Oral Radiol Endod* 2006; 101:542-547.
20. Tasdemir T, Er K, Yildirim T, Çelik D. Efficacy of three rotary NiTi instruments in removing gutta-percha from root canals. *Int Endod J* 2008; 41:191-196.
21. Aydin B, Kose T, Caliskan MK. Effectiveness of HERO 642 versus Hedstrom files for removing gutta-percha fillings in curved root canals: an ex vivo study. *Int Endod J* 2009; 42: 1050-1056.
22. Xiangya Huang, Junqi Ling, Xi Wei and Lisha Gu. Quantitative evaluation of debris extruded apically by using ProTaper Universal Tulsa Rotary system in endodontic re-treatment. *J Endod* 2007; 33:1102-1105.
23. Celik Unal G, Ureyen Kaya B, Tac AG, Kececi AD. A Comparison of the efficacy of conventional and new re-treatment instruments to remove gutta-percha in curved root canals: an ex vivo study. *Int Endod J* 2009; 42: 344-350.
24. Fenoul G, Meless GD, Pe rez F. The efficacy of R-Endo\_rotary NiTi and stainless-steel hand instruments to remove gutta-percha and resilon. *Int Endod J* 2010; 43: 135-141.
25. Ferreira JJ, Rhodes JS and Pitt Ford T. The efficacy of gutta-percha removal using ProFiles. *Int Endod J* 2001; 34: 267-274.
26. Gu LS, Ling JQ, Wei X, Huang XY. Efficacy of ProTaper Universal rotary retreatment system for gutta-percha removal from root canals. *Int Endod J* 2008; 41: 288-295.
27. Robertson D, Leeb JJ, McKee M and Brewer E. A clearing technique for the study of root canal systems. *J Endod* 1980; 6:421-424.
28. Somma F, Cammarota G, Plotino G, Rahde NM and Pameijer CH. The effectiveness of manual and mechanical instrumentation for the re-treatment of Three different root canal filling materials. *J Endod* 2008; 34:466-469.
29. Giuliani V, Cocchetti R and Pagavino G. Efficacy of ProTaper Universal re-treatment files in removing filling materials during root canal re-treatment. *J Endod* 2008; 34:1381-1384.
- 30.